

Incidental Primary Cystic Duct Lymph Node Tuberculosis in a 28-year-old Female: A Rare Case Report

PARIDHI¹, SHALINI BAHADUR², BHUVAN ADHLAKHA³, SHIVANI KALHAN⁴, MANABENDRA BAIDYA⁵

CC BY-NC-ND

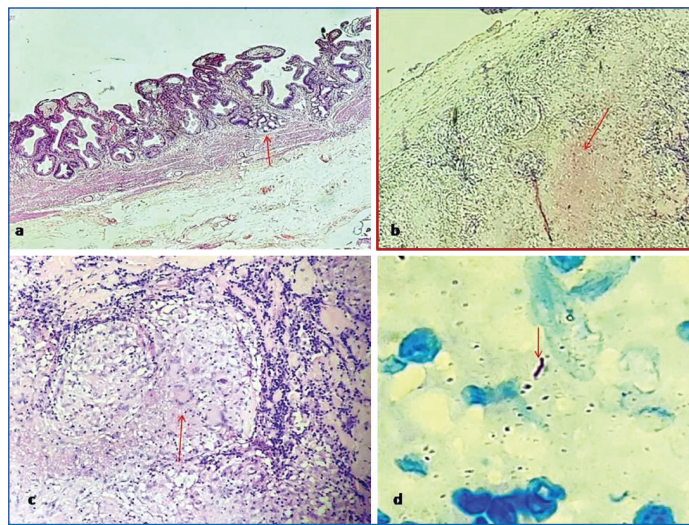
ABSTRACT

Tuberculosis (TB) is an infectious disease caused by acid-fast bacilli *Mycobacterium tuberculosis* (MTB). The lung remains the most common site involved by it. Extrapulmonary sites of TB are lymph nodes, pleura, bone, joints, urogenital tract, and meninges. Isolated Cystic Duct Tubercular Lymphadenitis (CDL TB) without involving the gallbladder is an uncommon manifestation of TB that primarily affects the lymph nodes around the cystic duct. A multidisciplinary approach is essential for accurate diagnosis and successful management of such cases. The authors hereby present a case of a 28-year-old female, without any evidence of TB elsewhere and an incidental finding of CDL TB. "The patient was sent with a clinical diagnosis of Chronic Calculus Cholecystitis (CCC)". This highlights the need for comprehensive clinical evaluation and diagnostic investigations to avoid misdiagnosis or delayed management. This underscores the significance of maintaining a high index of suspicion for extrapulmonary TB, particularly in regions where the disease remains endemic. Healthcare practitioners should be vigilant when encountering unusual clinical presentations or when dealing with atypical combinations of gallbladder pathologies, as illustrated by the concurrent occurrence of CDL TB with CC with evidence of Pyloric Metaplasia (PM) and cholesterosis without cholelithiasis, as in the patient of the present case report.

Keywords: Acid-fast bacilli, Cholelithiasis, Chronic cholecystitis, Cystic duct tubercular lymphadenitis

CASE REPORT

A 28-year-old married female (Gravida1 Parity1) presented with right upper quadrant non radiating abdominal pain for three months and intermittent fever and vomiting for one month. Pain was relieved on taking medication. There was no aggravating factor. There was no history of cough, haemoptysis, anorexia, weight loss, night sweats, diarrhoea, dysuria, haematemesis or melaena. Her past history and family history were also insignificant. There was no history of contact with tuberculosis (TB) patients. On examination, her vitals were stable, and tenderness in the right upper quadrant with a positive Murphy's sign was noted. There was no organomegaly. Laboratory investigations showed anaemia [Haemoglobin (Hb) 9.6 g/dL]. Other laboratory parameters were within normal limits. Abdominal Ultrasonography (USG) revealed dilated gallbladder with gallstones, suggestive of cholelithiasis and chronic cholecystitis. However, there was no mention of the cystic duct lymphadenopathy. Laparoscopic cholecystectomy was performed. The excised gallbladder was sent for Histopathological Examination (HPE). On gross examination, gallbladder specimen measuring 6×2×2 cm was received. External surface was unremarkable and wall thickness measured 0.3 cm. However, no stone was identified. A lymph node measuring 0.8×0.5 cm was identified near the cystic duct and the cut surface was grey-white. Microscopic examination showed features of Chronic Cholecystitis (CC) with Cholesterosis and Pyloric Metaplasia (PM) [Table/Fig-1a]. Lymph node revealed multiple epithelioid cell granulomas with central caseous necrosis and lymphocytic cuffing and Langhans-type giant cells [Table/Fig-1b,c]. Ziehl-Neelsen stain demonstrated Acid-fast Bacilli (AFB) [Table/Fig-1d]. A final diagnosis of Incidental CDL TB with CC with PM and cholesterosis was rendered. On follow-up, Computed Tomography (CT) scan of the abdomen was done 10 days after the operation, which showed no abdominal lymphadenopathy or evidence of any other abdominal pathology. Sputum smears done for demonstration of AFB were inconclusive. On follow-up, the



[Table/Fig-1]: a) Gallbladder wall showing Chronic Cholecystitis (CC) with Pyloric Metaplasia (PM) (↑) (H&E; 40x); b) Low power view of the cystic duct lymph node showing caseous necrosis (↑) (H&E; 40x); c) High power view of cystic duct lymph node showing epithelioid cell granuloma with Langhans giant cell (↑) and caseous necrosis (H&E; 400x); d) Acid-fast bacilli (AFB) (↑) on Ziehl-Neelsen stain (H&E; 1000x oil immersion).

patient had taken antitubercular drugs for three months and had no complaints till now.

DISCUSSION

The TB is a widespread infectious disease involving around 20-43% of the world's population [1]. Lungs are most affected by *Mycobacterium tuberculosis* (MTB) infection. The second most commonly involved system is the Gastrointestinal (GI) tract. However, hepatobiliary system involvement is very rare, accounting for 1% of total cases [2]. Involvement of Cystic Duct Lymph nodes (CDL) by TB is extremely rare and only few cases of isolated Cystic Duct Tubercular Lymphadenitis (CDL TB) without affecting the gallbladder are documented in the literature [2,3].

Biliary TB occurs either by direct biliary contaminations from swallowed mycobacterium or extension from adjacent affected structures and rarely by haematogenous spread [4].

In 1985, the first laparoscopic cholecystectomy was performed; thereafter it has become the procedure of choice for gallbladder removal. It is one of the commonest surgeries performed worldwide, mostly for gall stones [5]. CDL is typically found in Calot's triangle, superficial to cystic artery and lateral to bile duct. It is also known as cystic lymph node of Lund or Mascagni's node [6]. Among the spectrum of causes of CDL, enlargement reactive lymphadenopathy in the context of CC is most common, followed by sinus histiocytosis, metastasis, lymphoma, and TB. Other rare causes include lipid histiocytosis or ectopic tissue from various organs such as the pancreas [7,8].

TB is a globally prevalent infectious disease, primarily affecting the lungs. While TB primarily affects the lungs, extrapulmonary manifestations can occur, including lymphadenitis in various regions of the body [9].

The prevalence of CDL TB is relatively low, and the condition is more commonly seen in regions with a high burden of TB. Factors such as immunosuppression, crowded living conditions, and inadequate healthcare access may contribute to its occurrence. Isolated tuberculous involvement of the CDL is exceedingly rare [9,10].

Patients with CDL TB often present with nonspecific symptoms, including abdominal pain, discomfort, and jaundice [11]. Preoperative diagnosis of isolated CDL TB is a challenge as it is often missed clinically or radiologically [3]. The presence of an enlarged lymph node adjacent to the cystic duct raised suspicions of malignancy. Accurate diagnosis of CDL TB requires a combination of clinical assessment, imaging studies (USG, CT), and laboratory tests (TB culture, Polymerase Chain Reaction (PCR)). Fine-needle Aspiration Cytology (FNAC) or biopsy of affected lymph nodes may provide essential diagnostic information [2,3,9]. The index case demonstrated CDL TB that was diagnosed erroneously as a cystic duct stone on USG and a thickening or impacted stone in the wall preoperatively. The final diagnosis of CDL TB was rendered on HPE.

According to Ghazanfar A et al., diagnosis of CDL TB can be made if HPE demonstrates the presence of caseating granulomatous lymphadenitis with Langhans type of giant cell or demonstration of AFB in histopathology or PCR or culture positivity of MTB [3].

Isolated CDL TB without involving gallbladder has not been classified anywhere in the literature and so far only four cases have been described in the literature without any evidence of TB anywhere [1-3,11]. The index case is similar to Sali G et al., de Melo VA et al and Ghazanfar A et al., where the patients underwent cholecystectomy for cholelithiasis and after HPE were diagnosed as CDL TB without the involvement of gallbladder [1-3]. The coexistence of CDL TB with CC and without cholelithiasis in the present case further complicated the diagnostic process. The enlarged lymph node adjacent to the cystic duct raised suspicions of malignancy, illustrating the importance of considering atypical aetiologies even in cases where conventional diagnoses seem apparent. The identification of caseous necrosis and AFB on Ziehl-Neelsen staining provided definitive evidence of mycobacterial infection. The index case is even rarer as there was no evidence of cholelithiasis as in the previously discussed cases and additionally, gallbladder showed cholesterosis and PM.

The treatment approach typically involves a combination of anti-tubercular medications, including isoniazid, rifampicin, ethambutol, and pyrazinamide [12]. The successful management of the presented case involved a multidisciplinary approach, integrating both medical and surgical interventions. The initiation of antitubercular therapy in tandem with surgical removal of the gallbladder ensured comprehensive treatment. This underscores the importance of interdisciplinary collaboration in optimising patient outcomes, especially in complex cases with multiple co-existing pathologies.

With early diagnosis and appropriate treatment, the prognosis for CDL TB is generally favourable [11]. However, delayed diagnosis or inadequate treatment may lead to complications such as biliary obstruction, cholangitis, or abscess formation. If the disease is not treated promptly, it will spread to the biliary tract. It may lead to biliary stricture, bilioma, and infected abscess. Surgical intervention may be necessary in cases of abscess formation or obstruction of the biliary system [3].

Despite the detailed analysis of this case, certain limitations warrant consideration. The rarity of this presentation hinders the establishment of generalisable conclusions. Future research efforts should focus on accumulating more cases through multi-centre collaborations or retrospective analyses to enhance our understanding of the epidemiology, clinical characteristics, and optimal management approaches for similar cases.

CONCLUSION(S)

The present case report highlights the importance of considering TB as a differential diagnosis in patients presenting with gallbladder and biliary tract pathologies, especially when an unusual presentation or concomitant lymphadenopathy is observed. Prompt diagnosis and appropriate treatment are crucial for favourable patient outcomes.

REFERENCES

- [1] Sali G, Ali I, Sethi G, Singh G. Incidental cystic duct lymph node tuberculosis. *Int J Case Rep Images*. 2013;4(6):337-40.
- [2] de Melo VA, de Melo GB, Silva RL, Piva N, Almeida ML. Tuberculosis of the cystic duct lymph node. *Braz J Infect Dis*. 2004;8(1):112-14. Doi: 10.1590/s1413-6702004000100009. Epub 2004 Jul 20. PMID: 15286883.
- [3] Ghazanfar A, Asghar A, Khan NU, Hassan I. Primary tuberculosis of cystic duct lymph node. *BMJ Case Rep*. 2017;2017:bcr2016218804. Doi: 10.1136/bcr-2016-218804. PMID: 28623190; PMCID: PMC5534743.
- [4] Pang L, Wu S, Kong J. Hepatic hilar mass in an adolescent: A rare case of hepatobiliary tuberculosis. *BMC Infect Dis*. 2019;19(1):217. Doi: 10.1186/s12879-019-3850-5. PMID: 30832669; PMCID: PMC6398219.
- [5] Reynolds W Jr. The first laparoscopic cholecystectomy. *JLS*. 2001;5(1):89-94. PMID: 11304004; PMCID: PMC3015420
- [6] Tiang KW, Peng JX, Wysocki AP. Cystic artery lymph node-is it a fixed important landmark during cholecystectomy? *Liver Pancreat Sci*. 2017;2(2):1-2. Doi: 10.15761/LPS.1000114.
- [7] Al-Janabi MH, Ismail L, Wassouf MY, Sulaiman J, Salloum R, Al-Shehabi Z. Heterotopic pancreatic tissue in the gall bladder neck and lymph node surrounding cystic duct identified during cholecystectomy for chronic calculous cholecystitis: A rare case report from Syria. *Oxf Med Case Reports*. 2022;2022(6):omac068. Doi: 10.1093/omcr/omac068. PMID: 35769182; PMCID: PMC9235014.
- [8] Handra-Luca A, Ben Romdhane MH, Straub BK. Lipid histiocytosis of the gallbladder neck lymph node. *Case Rep Pathol*. 2016;2016:1061507. Available: <https://doi.org/10.1155/2016/1061507>.
- [9] Bomanji JB, Gupta N, Gulati P, Das CJ. Imaging in tuberculosis. *Cold Spring Harb Perspect Med*. 2015;5(6):a017814. Doi: 10.1101/cshperspect.a017814. PMID: 25605754; PMCID: PMC4448708.
- [10] Chakaya J, Petersen E, Nantanda R, Mungai BN, Migliori GB, Amanullah F, et al. The WHO Global Tuberculosis 2021 Report- not so good news and turning the tide back to End TB. *Int J Infect Dis*. 2022;124(Suppl 1):s26-29.

- [11] Heo TG, Hong SW, Chang YG, Lee WY, Ohe HJ, Choi KW, et al. Tuberculosis of cystic duct lymph node associated with cholecystitis. *Korean J Gastroenterol.* 2021;78(4):245-48. Available from: <https://doi.org/10.4166/kjg.2021.070>.
- [12] Sotgiu G, Centis R, D'ambrosio L, Migliori GB. Tuberculosis treatment and drug regimens. *Cold Spring Harb Perspect Med.* 2015;5(5):a017822. Doi: 10.1101/cshperspect.a017822. PMID: 25573773; PMCID: PMC4448591.

PARTICULARS OF CONTRIBUTORS:

1. Senior Resident, Department of Pathology, Government Institute of Medical Sciences, Greater Noida, Uttar Pradesh, India.
2. Professor, Department of Pathology, Government Institute of Medical Sciences, Greater Noida, Uttar Pradesh, India.
3. Assistant Professor, Department of Pathology, Government Institute of Medical Sciences, Greater Noida, Uttar Pradesh, India.
4. Professor and Head, Department of Pathology, Government Institute of Medical Sciences, Greater Noida, Uttar Pradesh, India.
5. Assistant Professor, Department of Surgery, Government Institute of Medical Sciences, Greater Noida, Uttar Pradesh, India.

NAME, ADDRESS, E-MAIL ID OF THE CORRESPONDING AUTHOR:

Paridhi,
Senior Resident, Department of Pathology, Government Institute of Medical Science, Greater Noida-201310, Uttar Pradesh, India.
E-mail: paridhi.dr@gmail.com

PLAGIARISM CHECKING METHODS: [\[Jain H et al.\]](#)

- Plagiarism X-checker: Dec 16, 2023
- Manual Googling: Feb 14, 2024
- iThenticate Software: Feb 19, 2024 (12%)

ETYMOLOGY: Author Origin**EMENDATIONS:** 6**AUTHOR DECLARATION:**

- Financial or Other Competing Interests: None
- Was Ethics Committee Approval Obtained for this study? No
- Was informed consent obtained from the subjects involved in the study? Yes
- For any images presented appropriate consent has been obtained from the subjects. Yes

Date of Submission: **Dec 16, 2023**Date of Peer Review: **Feb 01, 2024**Date of Acceptance: **Feb 20, 2024**Date of Publishing: **May 01, 2024**